

- Intended uses
- Implant techniques
- Removal and cares
- Special Protheses

# **STENING®**

---

**AIRWAY SILICONE DEVICES**



**ANIMUS BEYFORD**  
TRADING

**STENING®**  
 Animus Beyford Trading SL  
Av. Alfredo Palma 24  
29603 - Malaga - Spain



**MED**

ISO 13485

<https://stening.es>

## Tracheal T-Tube

Code: TM



*The Tracheal T-Tube makes possible the maintenance of an adequate caliber in the airway. It can act as a support for the tracheal wall in the stenosis treatment.*

*The external branch of the Tracheal T-Tubes prevents displacement and permits the aspiration of bronchial secretions.*

### Indications:

- Tracheal stenosis
- Subglottic stenosis
- Laryngotracheal stenosis
- After a tracheal resection and a termino-terminal anastomosis
- Tracheal reconstruction
- Larynx or trachea trauma
- Conventional tracheal cannula substitution

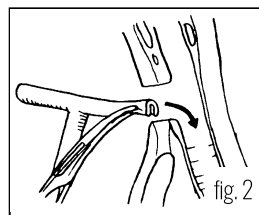
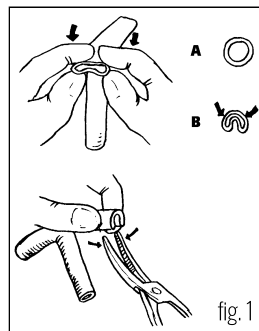
### How to Use

#### Insertion:

The procedure is usually performed in the same operating room and under the effect of the general anesthesia that was available for tracheal repair, but it can also be done under local anesthesia. Two curved forceps and aspiration system will be required. The lower branch of the "T" tube must be folded at its end (fig.1), to facilitate its introduction through the tracheal osteoma.

The curved forceps will maintain the tube on a folded position (fig. 2). Then the assembly will be introduced inside the trachea through the tracheostomy hole (fig. 3).

The second forceps will secure the T-tube by its external branch, thus avoiding an unwanted displacement (fig.4). Mobilize the T-Tube until its upper branch enters the trachea and lodges on its inside, occupying the tracheal portion adjacent to the vocal cords (fig.5). Finally, the ring with the lid must be collocated on the outer branch of the "T" tube. To do this, you can thread the ring in the forceps, grab the outer branch of the "T" tube and slide the ring until it is close to the neck skin, interposing a gauze between the skin and the ring. Occlude the external branch with the provided lid.



#### The tape method:

It is a very clever and useful resource that consists of using a ribbon about 80 cm long, which can be carried out with a narrow bandage.

It must be introduced through the end of the external branch of the T-tube, and guided it all along the tube's interior so that it gets out through the upper tracheal branch. Then you should take that bandage end and, with the help of a forceps, introduce it through the tracheostomy hole until it reaches the inside of the trachea. A second long forceps is inserted inside the bronchoscope until it arrives and takes the end of the tape that had been left inside the trachea and, pulling on it, the tape then will travel around the inside of the bronchoscope or tracheoscope until it appears on the proximal end. So we have now a thin ribbon that enters the outer branch of the "T" tube and gets out through our bronchoscope.

As always, the lower branch of the T-Tube always lodges easily in the distal trachea, but the upper branch may remain folded, or half of its distance in the glottis' direction. At the moment of tensing tape that we have placed, taking it by its ends, the branches of the T-tube will be easily aligned following the alternative that the tape occupies, accommodating the tube in a safe way. Additionally, the tape method avoids the accidental displacement of the T-tube during the implant maneuver.

#### Removal:

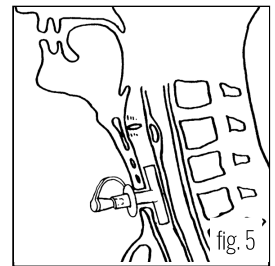
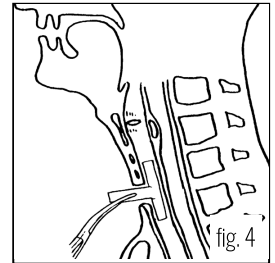
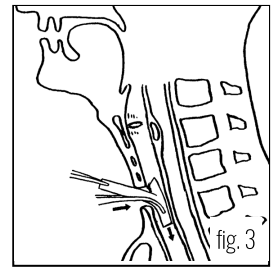
The Tracheal T-Tube can be easily removed by taking it by its external branch and pulling. This traction causes the fold of its internal branches that will meet, thus abandoning the trachea through the osteoma, following the direction of the force that pulls from it, from the outside.

The removal can be done if the treatment time is completed or to carry out a T-tube replacement. The most delicate extraction can also be carried out using a straight laryngoscope or a tracheoscope that, when introduced into the airway, allows to visualize the end of the T-tube. Take the T-tube through the tracheoscope, while an assistant sections with a pair of scissors the outer branch of the tube at the closest point from the trachea. Next, the T-tube will be removed with a forceps through the tracheoscope channel.

Other forms of insertion and removal are possible depending on the experience and preferences of the physician.

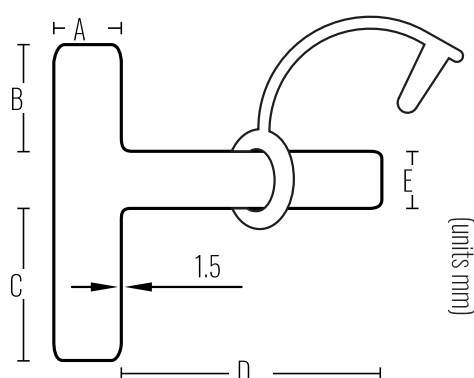
#### Anesthesia through the T-Tube:

Anesthesia through the Tracheal T-tube is possible. The upper branch must be included to avoid the loss of anesthetic gases. This can be achieved by inflating the balloon of a catheter that, introduced nasally, must cross the vocal cords and lodge within the upper branch of the Stening® T-Tube. Since the tracheal T-tube lacks of an inflatable balloon, positive pressure ventilation can cause a variable loss of air volume administered, and will depend on the greater or lesser space between the wall of the tube and the trachea.



## Postoperative Cares:

- Perform washes and aspirations frequently.
- Both internal branches must be suctioned. A thin catheter connected to the aspiration system can be used. To guide the catheter in the upper or lower direction within the Stening® T-tube, the external branch can be tilted in the opposite direction to the one that is going to be suctioned.
- Aspiration can also be done with the help of a flexible bronchoscope.
- Once the aspiration has been completed the external branch must remain permanently closed.
- Keep the external branch occluded with the lid provided for that purpose to permit moist and warm air inhalation through the upper airway and reduce the volume of secretions.
- Clean the skin that surrounds the tube a couple of times a day.
- The instructions may vary for each case and must be adjusted and provided to the patient and his relatives by the physician.



## Warning:

- Keep the external branch occluded permanently with the lid provided.
- In the presence of stridor, difficult breathing or any other anomaly, remove the external lid and consult the specialist immediately.

## Features

- Medical grade silicone
- Bevelled edges to prevent granulomas
- Removable
- Surface of maximum softness to avoid adherence of secretions
- Transparent or Radiopaque

References		Dimensions (mm)				
Translucent	Radiopaque	Diameter (A)	B	C	D	E
TM10	TMX10	10	20	29	50	11
TM11	TMX11	11	20	29	50	11
TM12	TMX12	12	23	32	60	11
TM13	TMX13	13	24	33	60	11
TM14	TMX14	14	26	35	70	11
TM15	TMX15	15	26	36	70	11
TM16	TMX16	16	27	37	70	11
TM18	TMX18	18	27	37	70	11

Stening® provides detailed instructions for use with each device, including insertion and removal techniques, precautions, and postoperative care.

For custom made devices you can [contact us](#)


A radiopaque device can be white or pale yellow.

Due to the characteristics of the production process, the sizes of the devices may vary by +/- 2%

**Warning:** the product should not be reused because this can cause cross contamination.

## Long Tracheal T-Tube

Code: TML



*The Tracheal T-Tube makes possible the maintenance of an adequate caliber in the airway. It can act as a support for the tracheal wall in the stenosis treatment.*

*The external branch of the Tracheal T-Tubes prevents displacement and permits the aspiration of bronchial secretions.*

### Indications:

- Distal, precarinal and tracheal injuries
- Tracheal stenosis
- Subglottic stenosis
- Laryngotracheal stenosis
- After a tracheal resection and a termino-terminal anastomosis
- Tracheal reconstruction
- Larynx or trachea trauma
- Conventional tracheal cannula substitution

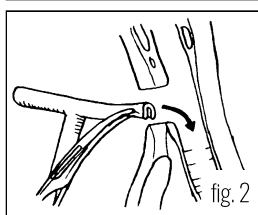
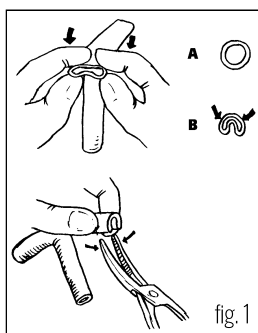
### How to Use

#### Insertion:

The procedure is usually performed in the same operating room and under the effect of the general anesthesia that was available for tracheal repair, but it can also be done under local anesthesia. Two curved forceps and aspiration system will be required. The lower branch of the "T" tube must be folded at its end (fig.1), to facilitate its introduction through the tracheal osteoma.

The curved forceps will maintain the tube on a folded position (fig. 2). Then the assembly will be introduced inside the trachea through the tracheostomy hole (fig. 3).

The second forceps will secure the T-tube by its external branch, thus avoiding an unwanted displacement (fig.4). Mobilize the T-Tube until its upper branch enters the trachea and lodges on its inside, occupying the tracheal portion adjacent to the vocal cords (fig.5). Finally, the ring with the lid must be collocated on the outer branch of the "T" tube. To do this, you can thread the ring in the forceps, grab the outer branch of the "T" tube and slide the ring until it is close to the neck' skin, interposing a gauze



between the skin and the ring. Occlude the external branch with the provided lid.

#### The tape method:

It is a very clever and useful resource that consists of using a ribbon about 80 cm long, which can be carried out with a narrow bandage.

It must be introduced through the end of the external branch of the T-tube, and guided it all along the tube's interior so that it gets out through the upper tracheal branch. Then you should take that bandage end and, with the help of a forceps, introduce it through the tracheostomy hole until it reaches the inside of the trachea. A second long forceps is inserted inside the bronchoscope until it arrives and takes the end of the tape that had been left inside the trachea and, pulling on it, the tape then will travel around the inside of the bronchoscope or tracheoscope until it appears on the proximal end. So we have now a thin ribbon that enters the outer branch of the "T" tube and gets out through our bronchoscope.

As always, the lower branch of the T-Tube always lodges easily in the distal trachea, but the upper branch may remain folded, or half of its distance in the glottis' direction. At the moment of tensing tape that we have placed, taking it by its ends, the branches of the T-tube will be easily aligned following the alternative that the tape occupies, accommodating the tube in a safe way. Additionally, the tape method avoids the accidental displacement of the T-tube during the implant maneuver.

#### Removal:

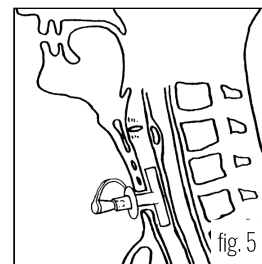
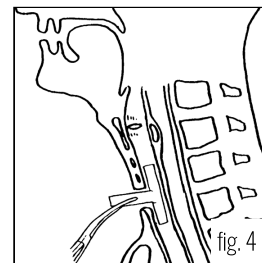
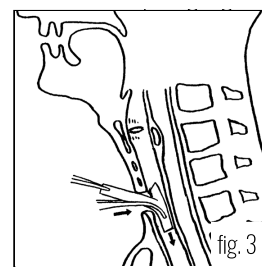
The Tracheal T-Tube can be easily removed by taking it by its external branch and pulling. This traction causes the fold of its internal branches that will meet, thus abandoning the trachea through the osteoma, following the direction of the force that pulls from it, from the outside.

The removal can be done if the treatment time is completed or to carry out a T-tube replacement. The most delicate extraction can also be carried out using a straight laryngoscope or a tracheoscope that, when introduced into the airway, allows to visualize the end of the T-tube. Take the T-tube through the tracheoscope, while an assistant sections with a pair of scissors the outer branch of the tube at the closest point from the trachea. Next, the T-tube will be removed with a forceps through the tracheoscope channel.

Other forms of insertion and removal are possible depending on the experience and preferences of the physician.

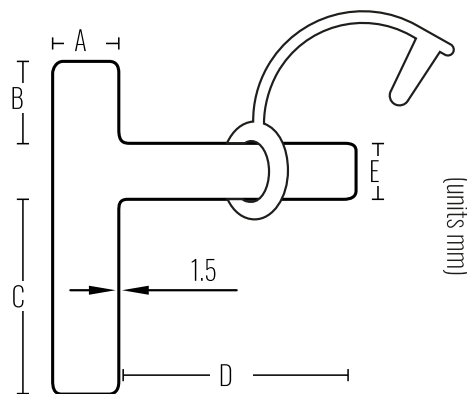
#### Anesthesia through the T-Tube:

Anesthesia through the Tracheal T-tube is possible. The upper branch must be included to avoid the loss of anesthetic gases. This can be achieved by inflating the balloon of a catheter that, introduced nasally, must cross the vocal cords and lodge within the upper branch of the Stening® T-Tube. Since the tracheal T-tube lacks of an inflatable balloon, positive pressure ventilation can cause a variable loss of air volume administered, and will depend on the greater or lesser space between the wall of the tube and the trachea.



### Postoperative Cares:

- Perform washes and aspirations frequently.
- Both internal branches must be suctioned. A thin catheter connected to the aspiration system can be used. To guide the catheter in the upper or lower direction within the Stening® T-tube, the external branch can be tilted in the opposite direction to the one that is going to be suctioned.
- Aspiration can also be done with the help of a flexible bronchoscope.
- Once the aspiration has been completed the external branch must remain permanently closed.
- Keep the external branch occluded with the lid provided for that purpose to permit moist and warm air inhalation through the upper airway and reduce the volume of secretions.
- Clean the skin that surrounds the tube a couple of times a day.
- The instructions may vary for each case and must be adjusted and provided to the patient and his relatives by the physician.



### Warning:

- Keep the external branch occluded permanently with the lid provided.
- In the presence of stridor, difficult breathing or any other anomaly, remove the external lid and consult the specialist immediately.

### Features

- Medical grade silicone
- Bevelled edges to prevent granulomas
- Removable
- Surface of maximum softness to avoid adherence of secretions
- Transparent or Radiopaque

References		Dimensions (mm)				
Translucent	Radiopaque	Diameter (A)	B	C	D	E
TML10	TMLX10	10	35	75	50	11
TML11	TMLX11	11	35	75	50	11
TML12	TMLX12	12	35	75	60	11
TML13	TMLX13	13	35	75	60	11
TML14	TMLX14	14	35	75	70	11
TML15	TMLX15	15	35	75	70	11
TML16	TMLX16	16	35	75	70	11
TML18	TMLX18	18	35	75	70	11

Stening® provides detailed instructions for use with each device, including insertion and removal techniques, precautions, and postoperative care.

For custom made devices you can [contact us](#)

A radiopaque device can be white or pale yellow.

Due to the characteristics of the production process, the sizes of the devices may vary by +/- 2%

**Warning:** the product should not be reused because this can cause cross contamination.

## Tracheal T-Tube XL

Code: TML2



*This T-tube has a thinner cephalic branch that facilitates its location in the proximal trachea, in the subglottis and, if preferred, through the vocal cords.*

*The external branch of the "T" tracheal tubes prevents displacement and allows aspiration of bronchial secretions.*

### Indications:

- Distal, precarinal and tracheal injuries
- Tracheal stenosis
- Subglottic stenosis
- Laryngotracheal stenosis
- After a tracheal resection and a termino-terminal anastomosis
- Tracheal reconstruction
- Larynx or trachea trauma
- Conventional tracheal cannula substitution

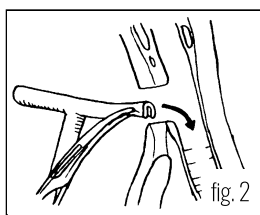
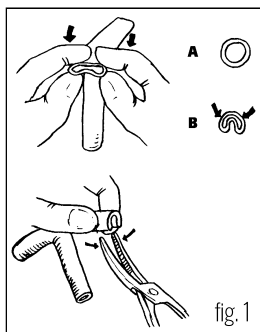
### How to Use

#### Insertion:

The procedure is usually performed in the same operating room and under the effect of the general anesthesia that was available for tracheal repair, but it can also be done under local anesthesia. Two curved forceps and aspiration system will be required. The lower branch of the "T" tube must be folded at its end (fig.1), to facilitate its introduction through the tracheal osteoma.

The curved forceps will maintain the tube on a folded position (fig. 2). Then the assembly will be introduced inside the trachea through the tracheostomy hole (fig. 3).

The second forceps will secure the T-tube by its external branch, thus avoiding an unwanted displacement (fig.4). Mobilize the T-Tube until its upper branch enters the trachea and lodges on its inside, occupying the tracheal portion adjacent to the vocal cords (fig.5). Finally, the ring with the lid must be collocaded on the outer branch of the "T" tube. To do this, you can thread the ring in the forceps, grab the outer branch of the "T" tube and slide the ring until it is close to the neck' skin, interposing a gauze



between the skin and the ring. Occlude the external branch with the provided lid.

#### The tape method:

It is a very clever and useful resource that consists of using a ribbon about 80 cm long, which can be carried out with a narrow bandage.

It must be introduced through the end of the external branch of the T-tube, and guided it all along the tube's interior so that it gets out through the upper tracheal branch. Then you should take that bandage end and, with the help of a forceps, introduce it through the tracheostomy hole until it reaches the inside of the trachea. A second long forceps is inserted inside the bronchoscope until it arrives and takes the end of the tape that had been left inside the trachea and, pulling on it, the tape then will travel around the inside of the bronchoscope or tracheoscope until it appears on the proximal end. So we have now a thin ribbon that enters the outer branch of the "T" tube and gets out through our bronchoscope.

As always, the lower branch of the T-Tube always lodges easily in the distal trachea, but the upper branch may remain folded, or half of its distance in the glottis' direction. At the moment of tensing tape that we have placed, taking it by its ends, the branches of the T-tube will be easily aligned following the alternative that the tape occupies, accommodating the tube in a safe way. Additionally, the tape method avoids the accidental displacement of the T-tube during the implant maneuver.

#### Removal:

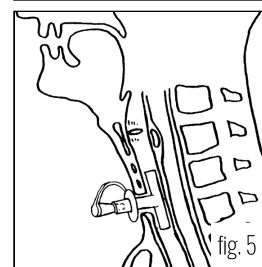
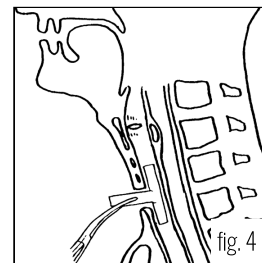
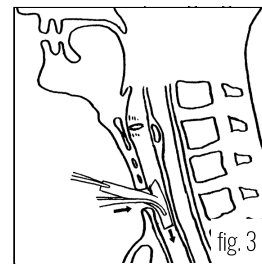
The Tracheal T-Tube can be easily removed by taking it by its external branch and pulling. This traction causes the fold of its internal branches that will meet, thus abandoning the trachea through the osteoma, following the direction of the force that pulls from it, from the outside.

The removal can be done if the treatment time is completed or to carry out a T-tube replacement. The most delicate extraction can also be carried out using a straight laryngoscope or a tracheoscope that, when introduced into the airway, allows to visualize the end of the T-tube. Take the T-tube through the tracheoscope, while an assistant sections with a pair of scissors the outer branch of the tube at the closest point from the trachea. Next, the T-tube will be removed with a forceps through the tracheoscope channel.

Other forms of insertion and removal are possible depending on the experience and preferences of the physician.

#### Anesthesia through the T-Tube:

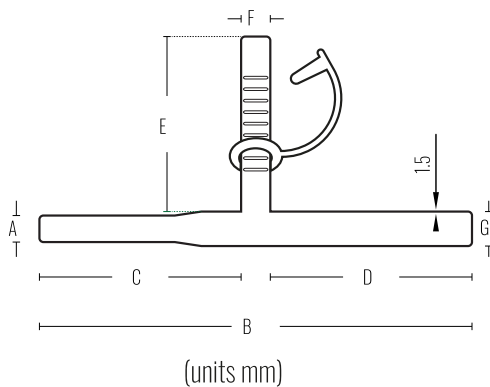
Anesthesia through the Tracheal T-tube is possible. The upper branch must be included to avoid the loss of anesthetic gases. This can be achieved by inflating the balloon of a catheter that, introduced nasally, must cross the vocal cords and lodge within the upper branch of the Stening® T-Tube. Since the tracheal T-tube lacks of an inflatable balloon, positive pressure ventilation can cause a variable loss of air volume administered, and will depend on the greater or lesser space between the wall of the tube and the trachea.





## Postoperative Cares:

- Perform washes and aspirations frequently.
- Both internal branches must be suctioned. A thin catheter connected to the aspiration system can be used. To guide the catheter in the upper or lower direction within the Stening® T-tube, the external branch can be tilted in the opposite direction to the one that is going to be suctioned.
- Aspiration can also be done with the help of a flexible bronchoscope.
- Once the aspiration has been completed the external branch must remain permanently closed.
- Keep the external branch occluded with the lid provided for that purpose to permit moist and warm air inhalation through the upper airway and reduce the volume of secretions.
- Clean the skin that surrounds the tube a couple of times a day.
- The instructions may vary for each case and must be adjusted and provided to the patient and his relatives by the physician.



## Warning:

- Keep the external branch occluded permanently with the lid provided.
- In the presence of stridor, difficult breathing or any other anomaly, remove the external lid and consult the specialist immediately.

When inserting the device remember to orient the wider branch caudally.

## Features

- Medical grade silicone
- Bevelled edges to prevent granulomas
- Removable
- Surface of maximum softness to avoid adherence of secretions
- Transparent or Radiopaque

References		Dimensions (mm)						
Translucent	Radiopaque	Diameter (A)	Length (B)	Length (C)	Length (D)	Length (E)	Diameter (F)	Diameter (G)
TML213	TML2X13	10	163	76	76	66	11	13

Stening® provides detailed instructions for use with each device, including insertion and removal techniques, precautions, and postoperative care.

For custom made devices you can [contact us](#)

A radiopaque device can be white or pale yellow.

Due to the characteristics of the production process, the sizes of the devices may vary by +/- 2%

**Warning:** the product should not be reused because this can cause cross contamination.

## Pediatric Angular Tracheal T-Tube

Code: TMPA



*The Tracheal T-Tube makes possible the maintenance of an adequate caliber in the airway. It can act as a support for the tracheal wall in the stenosis treatment.*

*The external branch of the Tracheal T-Tubes prevents displacement and permits the aspiration of bronchial secretions.*

*TMPA external branch has an angle of 70°.*

### Indications:

- Tracheal stenosis
- Laryngeal stenosis
- Laryngotracheal stenosis
- Segmental tracheal resection
- Support in tracheal reconstruction

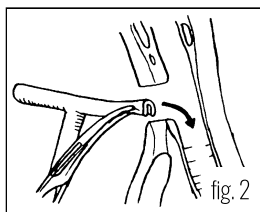
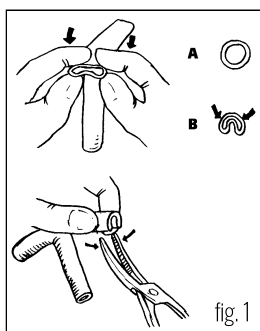
### How to Use

#### Insertion:

The procedure is usually performed in the same operating room and under the effect of the general anesthesia that was available for tracheal repair, but it can also be done under local anesthesia. Two curved forceps and aspiration system will be required. The lower branch of the "T" tube must be folded at its end (fig.1), to facilitate its introduction through the tracheal stenoma.

The curved forceps will maintain the tube on a folded position (fig. 2). Then the assembly will be introduced inside the trachea through the tracheostomy hole (fig. 3).

The second forceps will secure the T-tube by its external branch, thus avoiding an unwanted displacement (fig.4). Mobilize the T-Tube until its upper branch enters the trachea and lodges on its inside, occupying the tracheal portion adjacent to the vocal cords (fig.5). Finally, the ring with the lid must be collocated on the outer branch of the "T" tube. To do this, you can thread the ring in the forceps, grab the outer branch of the "T" tube and slide the ring until it is close to the neck' skin, interposing a gauze between the skin and the ring. Occlude the external branch with the provided lid.



#### The tape method:

It is a very clever and useful resource that consists of using a ribbon about 80 cm long, which can be carried out with a narrow bandage.

It must be introduced through the end of the external branch of the T-tube, and guided it all along the tube's interior so that it gets out through the upper tracheal branch. Then you should take that bandage end and, with the help of a forceps, introduce it through the tracheostomy hole until it reaches the inside of the trachea. A second long forceps is inserted inside the bronchoscope until it arrives and takes the end of the tape that had been left inside the trachea and, pulling on it, the tape then will travel around the inside of the bronchoscope or tracheoscope until it appears on the proximal end. So we have now a thin ribbon that enters the outer branch of the "T" tube and gets out through our bronchoscope.

As always, the lower branch of the T-Tube always lodges easily in the distal trachea, but the upper branch may remain folded, or half of its distance in the glottis' direction. At the moment of tensing tape that we have placed, taking it by its ends, the branches of the T-tube will be easily aligned following the alternative that the tape occupies, accommodating the tube in a safe way. Additionally, the tape method avoids the accidental displacement of the T-tube during the implant maneuver.

#### Removal:

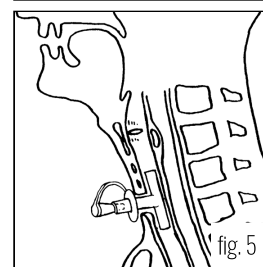
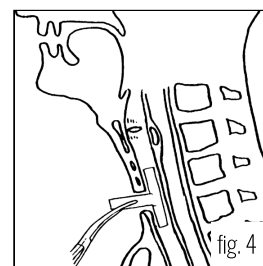
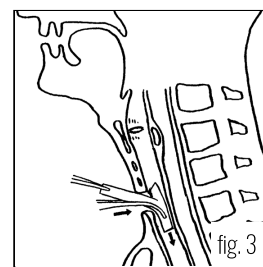
The Tracheal T-Tube can be easily removed by taking it by its external branch and pulling. This traction causes the fold of its internal branches that will meet, thus abandoning the trachea through the osteoma, following the direction of the force that pulls from it, from the outside.

The removal can be done if the treatment time is completed or to carry out a T-tube replacement. The most delicate extraction can also be carried out using a straight laryngoscope or a tracheoscope that, when introduced into the airway, allows to visualize the end of the T-tube. Take the T-tube through the tracheoscope, while an assistant sections with a pair of scissors the outer branch of the tube at the closest point from the trachea. Next, the T-tube will be removed with a forceps through the tracheoscope channel.

Other forms of insertion and removal are possible depending on the experience and preferences of the physician.

#### Anesthesia through the T-Tube:

Anesthesia through the Tracheal T-tube is possible. The upper branch must be included to avoid the loss of anesthetic gases. This can be achieved by inflating the balloon of a catheter that, introduced nasally, must cross the vocal cords and lodge within the upper branch of the Stening® T-Tube. Since the tracheal T-tube lacks of an inflatable balloon, positive pressure ventilation can cause a variable loss of air volume administered, and will depend on the greater or lesser space between the wall of the tube and the trachea.



## Postoperative Cares:

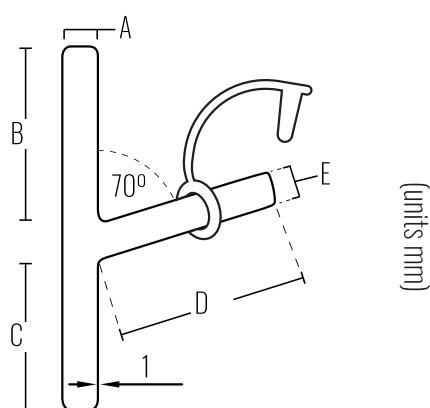
- Perform washes and aspirations frequently.
- Both internal branches must be suctioned. A thin catheter connected to the aspiration system can be used. To guide the catheter in the upper or lower direction within the Stening® T-tube, the external branch can be tilted in the opposite direction to the one that is going to be suctioned.
- Aspiration can also be done with the help of a flexible bronchoscope.
- Once the aspiration has been completed the external branch must remain permanently closed.
- Keep the external branch occluded with the lid provided for that purpose to permit moist and warm air inhalation through the upper airway and reduce the volume of secretions.
- Clean the skin that surrounds the tube a couple of times a day.
- The instructions may vary for each case and must be adjusted and provided to the patient and his relatives by the physician.

## Warning:

- Keep the external branch occluded permanently with the lid provided.
- In the presence of stridor, difficult breathing or any other anomaly, remove the external lid and consult the specialist immediately.

## Features

- Medical grade silicone
- Bevelled edges to prevent granulomas
- Removable
- Surface of maximum softness to avoid adherence of secretions
- Transparent or Radiopaque



References		Dimensions (mm)				
Translucent	Radiopaque	Diameter (A)	B	C	D	E
TMPA6	TMPAX6	6	56	40	40	6
TMPA7	TMPAX7	7	56	40	40	6
TMPA8	TMPAX8	8	56	40	40	8
TMPA9	TMPAX9	9	56	62	40	8

Stening® provides detailed instructions for use with each device, including insertion and removal techniques, precautions, and postoperative care.

For custom made devices you can [contact us](#)

A radiopaque device can be white or pale yellow.

Due to the characteristics of the production process, the sizes of the devices may vary by +/- 2%

**Warning:** the product should not be reused because this can cause cross contamination.

## Tracheostomy Tutor

Code: TU



*The Tracheostomy Tutor allows a secondary access to the airway.  
It replaces the conventional tracheal cannula providing comfort, reducing the production of secretions and facilitating phonation.  
Maintains the tracheostomy orifice permeable until its definitive closure is decided.*

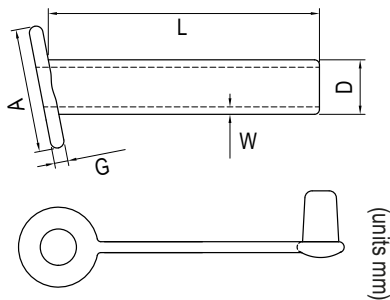
*The tutor is fixed in the osteoma of the anterior tracheal wall and in the planes of the neck. Its introduction into the tracheal clearance is minimal.*

*The ring of the outer branch keeps it in the desired position.*

*Its external branch must be included permanently, so that the entrance of warm and humid air by the upper airway is possible.*

### Indications:

- After removing a cannula or a T-tube, to avoid a definitive closure of the osteoma.
- Preserve the tracheostomy hole.



### How to Use:

The osteoma tutor is introduced through the already formed tracheal orifice. Previously the surrounding skin will be sanitized and an antiseptic solution will be applied.

Since the tutor is small, the use of a lubricant is optional.

The tutor is introduced by the stoma taking it between the thumb and forefinger or with the help of a curved forceps.

Already in position and as it proceeds after the placement of the T-Tube model, the ring that fixes the lid, separated from the skin by small gauze, will be applied.

To remove the tutor, you must pull from its external branch.

### Cares:

The portion of the tutor that lodges inside the trachea consists of two small fins that make accidental extraction difficult.

Therefore, there is no part of the device inside the trachea, as it happens with a conventional cannula, so that the aspiration from the tutor's interior is unnecessary.

It also has a lid on its external branch that makes the aspiration of tracheal secretions possible in cases where, due to the abundance of these, it is necessary.

### Features

- Medical grade silicone
- Bevelled edges to prevent granulomas
- Removable
- Surface of maximum softness to avoid adherence of secretions
- Transparent or Radiopaque

References		Dimensions (mm)				
Translucent	Radiopaque	Diameter (D)	Length (L)	Wall thickness (W)	Height (A)	Thickness (G)
TU11	TUX11	11	55	1.5	25	2.75
TU8	TUX8	8	55	1	16	2.75

Stening® provides detailed instructions for use with each device, including insertion and removal techniques, precautions, and postoperative care.

For custom made devices you can [contact us](#)

A radiopaque device can be white or pale yellow.

Due to the characteristics of the production process, the sizes of the devices may vary by +/- 2%

**Warning:** the product should not be reused because this can cause cross contamination.

## Laryngeal Stent

Code: LK / LP / LM / LG



The Stening® Laryngeal stent is a silicone prosthesis that copies the reliefs of the endolarynx. This flexible mould is an alternative to support the laryngeal skeleton in situations of organ trauma or after the reconstruction surgery. It has a very smooth surface and blunt edges that reduce traumatism on the mucosa. Its flexibility favors the tolerance and the solid conformation prevents its collapse and deformation.

The Stening® Laryngeal Stent is radiopaque and it is accompanied by four silicone discs that help on its external fixation.

### Indications:

- Laryngeal stenosis
- Surgical reconstruction
- Partial laryngectomies
- Severe burns

### How to Use:

The implantation of this stent requires a previous tracheostomy, because orinasal respiration will not be possible.

The surgical procedure will be the one of choice of the attending physician, but usually, in the cases of stenosis, an anterior and posterior laryngeal fissure with a graft of costal cartilage to achieve greater laryngeal stability is carried out.

Once the stent has been placed in the appropriate position, it can be fixed with two capitons following the path:

**[skin] - [subcutaneous planes] - [stent] - [soft tissues] - [skin]**

and it will remain in that place, acting as a tutor, as long as the doctor deems necessary for each case.

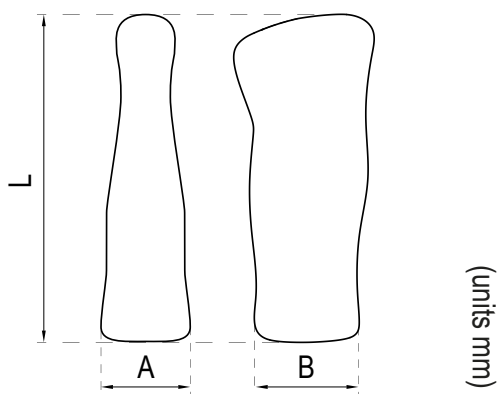
The extraction is done orally, removing it with a forceps that will take it by its upper end.

### Cares:

It does not require extra cares, just the ones carried out in the postoperative of laryngeal surgery.

### Features

- Medical grade silicone
- Bevelled edges to prevent granulomas
- Removable
- Surface of maximum softness to avoid adherence of secretions
- Radiopaque



References		Dimensions (mm)		
Translucent	Radiopaque	Length	A	B
-	LK	20 to 33	6 to 9	7 to 10
-	LP	36.8	9.7	9.9
-	LM	39	10	11.3
-	LG	46	15	15.6

Stening® provides detailed instructions for use with each device, including insertion and removal techniques, precautions, and postoperative care.

For custom made devices you can [contact us](#)

A radiopaque device can be white or pale yellow.

Due to the characteristics of the production process, the sizes of the devices may vary by +/- 2%

**Warning:** the product should not be reused because this can cause cross contamination.

## Pharyngeal Tube

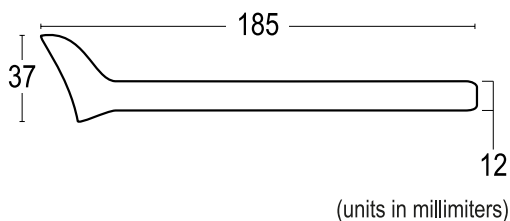
Code: TF



*It is made out of flexible silicone and is useful in a wide range of situations.*

*Its apical end is progressively enlarged, in this way the anterior edge maintains contact with the base of the tongue, while the posterior one rests on the pharyngeal wall. In that way, the saliva is stored in the oropharynx leading to esophagus, preventing the maceration of the tissues and avoiding the aspiration of the saliva towards the airway.*

*A nasointestinal tube for feeding can be inserted through the Pharyngeal Tube.*



### Indications:

- Secondary fistulas to laryngectomy, radiotherapy, neoplastic conditions, caustic ingestion
- Orocutaneous or pharyngocutaneous, traumatic fistula
- Head and neck oncological surgery
- Esophageal stenosis
- Esophagus carcinoma

### How to Use:

The introduction of the pharyngeal tube should be done under general anesthesia. It can be cut up to the length that is considered appropriate for the case.

A laryngoscope will be used to have convenient access to the larynx and adequate vision.

With the help of a hypopharyngoscope and a long forceps, take the tube by its distal end to lead it into the esophagus, until the proximal cup is at the laryngeal level. Previous esophageal dilatation may be necessary.

After its introduction it can be fixed with a percutaneous point.

### Cares:

Perform a periodic check-up carried out by the physician.

### Features

- Medical grade silicone
- Bevelled edges to prevent granulomas
- Removable
- Surface of maximum softness to avoid adherence of secretions
- Transparent or Radiopaque

References		Dimensions (mm)		
Translucent	Radiopaque	Width	Length	Diameter
TF12	TFX12	37	185	12

Stening® provides detailed instructions for use with each device, including insertion and removal techniques, precautions, and postoperative care.

For custom made devices you can [contact us](#)

A radiopaque device can be white or pale yellow.

Due to the characteristics of the production process, the sizes of the devices may vary by +/- 2%

**Warning:** the product should not be reused because this can cause cross contamination.

## References

- Montgomery, WW: Silicone Tracheal Canula. *Annals of Otolaryngology, Rhinology & Laryngology*, Vol 89 (6), pp 521-528, Nov/Dec 1980.
- Montgomery, WW: Manual for Care of the Montgomery Silicone Tracheal T-Tube. *Annals of Otolaryngology, Rhinology & Laryngology*, Vol 89, Supp 73, 1980.
- Lane GA, Stevede GM, and Pashley NRT. Anesthesia for the Patient with a Tracheal T-tube Stent. *Anesthesia and Analgesia* 1981; 218-219.
- Cooper JD, et al. Use the Silicone Tracheal T-tube for the Management of Complex Tracheal injuries. *Journal of Thoracic and Cardiovascular Surgery* 1981; 82, 4: 559-568.
- Montgomery, WW: Subglottic stenosis. *International surgery*; Cervese, Editor, Piccin Medical Books, Vol 67, pp. 199-207, 1982.
- Montgomery, WW and Montgomery, SK: Manual For Use of Montgomery Laryngeal, Tracheal and Esophageal Prostheses. *Annals of Otolaryngology, Rhinology & Laryngology*, Supp 125, Jul-Aug 1986.
- Colt HC, and Dumon JF. Airway Obstruction in Cancer: The Pros and the Cons of Stents. *Journal of Respiratory Disease* 1991; 12, 8: 741-749.
- Armin E, Feller-Kopman D, Becker D, Mehta AC: Central Airway Obstruction. *Am J Respir Crit Care Med* 2004; Vol 169: 1278-1297.
- Weber TR, Connors RH, and Tracy TF. Acquired Tracheal Stenosis in Infants and Children. *Journal of Thoracic and Cardiovascular Surgery* 1991; 102: 29-35.
- Maddaus MA, Toth JLR, Gullane PJ, Pearson FG. Subglottic Tracheal Resection and Synchronous Laryngeal reconstruction. *The Journal of Thoracic and Cardiovascular Surgery* 1992; 104: 1443-1450.
- Gaissert HA, Grillo HC, Mathisen DJ, Wain JC. Temporary and Permanent Restoration of Airway Continuity with the Tracheal T-tube. *Journal of Thoracic and Cardiovascular Surgery* 1994; 107: 600-606.
- Díaz-Jimenez JP, Ferrero Muñoz E, Martínez Ballarín JI, Kovitz KL, Manresa Presas F. Silicones Stents in the management of obstructive tracheobronchial lesions: 2 –year experience. *J Bronchol* 1994; 109:626-9.
- Colt HG, Dumon JF. Airway stents: present and future. *Clin Chest Med* 1995; 16:465-78.
- Cavaliere S, Venuta F, Foccoli P, Tonielli C, La Face B. Endoscopic treatment of malignant airway obstructions in 2008 patients. *Chest* 1996; 110: 1536-42.
- Dumon JF, Cavaliere S, Díaz Jimenez JP, et al. Seven-year experience with the Dumon prosthesis. *J Bronchol* 1996; 3:6-10.
- Donahue D, et al. Reoperative Tracheal Resection and Reconstruction for Unsuccessful Repair of Postintubation Stenosis. *Journal of Thoracic and Cardiovascular Surgery* 1997; 114: 34-939.
- Bollinger CT. Airway stents. *Semin Respir Crit Care Med* 1997; 18:563-70.
- Bolot G, Poupart M, Pignat JC, et al. Self expanding metal stents for the management of bronchial stenosis and bronchomalacia after lung transplantation. *Laryngoscope* 1998; 108:11230-3.
- Sichel, et al: Insertion of a Montgomery T-Tube. *The Laryngoscope*, Vol 108, pp. 1107-1108, July 1998.
- Filler RM, Forte V, Chait P. Tracheobronchial Stenting for the treatment of airway obstruction. *Pediatr Surg* 1998;33:304-11
- Miyazawa T, Arita K. Airway stenting in Japan. *Respirology* 1998; 3:229-34.
- Korpela A, Aarnio P, Sariola H, Tormala P, Harjula A. Bioabsorbable self-reinforced poly-L-lactide, metallic and Silicone stents in the management of experimental trachea stenosis. *Chest* 1999;115:490-5.
- Verneuil, A and Berke, G: Improved Method of insertion of a Montgomery T-Tube. *The Laryngoscope*, Vol 109, pp. 1351-1353, Aug 1999.
- Lee KW, Im JG, Han JL, Kim TK, Park JH, Yeon KM. Tuberculosis stenosis of the main bronchus: result of treatment with balloons and metallic stents. *J Vasc Interv Radiol*. 1999; 10:532-8.
- Dumon JF, Dumon MC. Dumon-Novatech Y-Stents: A Four-Year Experience with 50 tracheobronchial Tumors Involving the Carina. *J Bronchol* 2000; 7:26-32.
- Jantz, MA, Silvestri,GA. Controversy Silicone Stents versus Metal Stents for Management of Benign Tracheobronchial Disease. *J Bronchol* 2000; 7:177-183.
- Leon, et al: Montgomery Salivary Bypass Tube in the reconstruction of the Hypopharynx, Cost-Benefit Study. *Annals of Otolaryngology, Rhinology & Laryngology*, Vol.108 (9), pp.864-868, sept 1999.
- Spinelli, P, et al: Treatment of Nondilatable Malignant Pharyngoesophageal Strictures by Montgomery Salivary Bypass Tube: A New Approach. *Gastrointestinal Endoscopy*, Vol 41, N° 6, pp 601-603.
- Montgomery, WW:Current Modifications of the Salivary Bypass Tube and Tracheal T. Tube. *Annals of Otolaryngology, Rhinology & Laryngology*, Vol 95 (2), pp 121-125.
- Schaefer, SD: The Acute Management of External Laryngeal Trauma. *Archives of Otolaryngology – Head & Neck Surgery*, Vol 118, pp 598-604, june 1992.
- Grillo, HC: Primary Reconstruction of Airway After Resection of Subglottic Laryngeal and Upper Tracheal Stenosis. *Annals of Thoracic Surgeons*, pp. 3-18, Jan 1982.
- Flexon PB, Cheney ML, Montgomery WW and Turner PA: Management of Patients with Glottic and Subglottic Stenosis Resulting from Thermal Burns. *Annals of Otolaryngology & Laryngology*, Vol 98 (1), pp. 27-30, Jan 1989.
- Freidman M, Mayer AD: Laryngotracheal Reconstruction in Adults with the Sternocleidomastoid Myoperiosteal Flap. *Annals of Otolaryngology, Rhinology & Laryngology*, Vol 12, pp 897-908, Nov 1993.
- Boelcskei PL, Dierkesmann R, Bauer PC, Becker HD, Bolliger CT, Wolfgang FJ. Section on respiratory endoscopy of the German Society of Pulmonology. Recommendations for bronchoscopic treatment of tracheobronchial occlusions, stenoses, and mural malignant tumors. *J Bronchol*. 2000;7:133-8.
- Brichet A, Ramon P, Marquette C H: Sténoses et complications trachéales postintubation. *Clinique des maladies respiratoires, Hôpital A. Calmette, CHRU de Lille, France. (Reçue 9 novembre 2001; accepté le 10 novembre 2001).*
- A. Brichet, P. Ramon, C.H. Marquette Sténoses et complications trachéales postintubation Réanimation 2002; 11: 1-10.
- Hervé Dutau, Bénédicte Toutblanc, Carla Lamb and Luis Seijo: Use of the Dumon Y-stent in the Management of Malignant Disease Involving the Carina: A Retrospective Review of 86 Patients. *Chest* 2004;126:951-958.
- Noppen M, Stratakos G, D'Haese J, Meysman M and Vinken W: Removal of Covered Self-Expandable Metallic Airway Stents in Benign Disorders: Indications, Technique, and Outcomes. *Chest* 2005;127:482-487.
- A. Cosano Povedano, L. Muñoz Cabrera, F.J. Cosano Povedano, J. Rubio Sánchez, N. Pascual y A. Martínez Escribano Dueñas. Cinco años de experiencia en el tratamiento endoscópico de las estenosis de la vía aérea principal *Arch Bronconeumol*. 2005;41 (6):322-7.
- Amjadi K, Voduc N, Cruysberghs Y, Lemmens R, Fergusson, D A, Doucette S, Noppen M.:Impact of interventional Bronchoscopy on quality of life in malignant airway obstruction.
- Debais M., Vilas G., Boccia C. M., Isidoro R. Repermeabilización de la vía aérea con prótesis traqueobronquiales: 300 casos. *Rev Am Med Resp* 2012; 2: 38-43. *Respiration* 2008;76:421-428.
- Isidoro, R. Prótesis traqueal implante prolongado: 10 años. *RAMR* 2016; 3:250-257.

